



EFFECTIVE TATTOO REMOVAL TREATMENTS

PART TWO OF OUR TWO-PART SERIES DISCUSSES CURRENT TREATMENT MODALITIES AND POSSIBLE TECHNIQUES FOR THE FUTURE.

BY WILLIAM KIRBY, D.O., TEJAS DESAI, D.O., AND FRANCISCA KARTONO, B.S.

Human beings have been experimenting with tattoos since ancient times. And, it's likely, that as long as tattoos have been around so has the need for tattoo removal.

Through the years, many methods of removal have been attempted. As we discussed last month, some of the first attempts at removal were done through techniques such as dermabrasion, salabrasion, liquid nitrogen, and surgical excision among others. The advent of the laser brought new options for removal – beginning with the argon laser and CO₂ laser, which we also discussed last month. But these options have been replaced by newer options. Here, we'll discuss the three lasers most commonly used in tattoo removal — the quality switched (Q-switched) ruby (QSRL), Q-switched neodymium:yttrium-aluminum-garnet (QSNd:YAG), and Q-switched alexandrite (QSAlex) — and offer tips on choosing the best treatment for your patient.

THE Q-SWITCHED LASERS

Q-switching of a laser is a mechanism often used to control the light output by concentrating all the energy into intense bursts or series of pulses. To put it simply: The Q-switched lasers deliver a fast, powerful pulse. Due to their high energy and short pulse duration these lasers induce selective photothermolysis. The Q-switched lasers have uniformly replaced both the carbon dioxide and argon laser for the treatment of tattoo pigment.

Q-switched ruby laser (QSRL): The QSRL is a laser containing a ruby crystal of aluminum trioxide doped with chromium ions. Doping is a process in which the crystal is grown in the presence of an impurity so that the crystal lattice purposely forms with an impurity within it. A ruby rod is placed within the laser cavity where flashlamps excite the chromium ions to produce photons at a wavelength of 694 nm with 20 ns to 40 ns pulse durations. QSRL light penetrates about 1 mm into the skin and is well absorbed by black tattoo ink. This level of penetration is clinically advantageous for reaching

tattoo pigment located within the dermis. At a wavelength of 694 nm, the QSRL light is minimally absorbed by hemoglobin but is well absorbed by melanin.¹

In 1965, Goldman documented the earliest report of tattoo pigment interaction with Q-switched lasers.² Less than satisfactory results including necrosis and retention of tattoo ink were noted, however, Goldman continued to follow these patients and noted continued fading of the treated area with time.

In 1983 Reid et al published a report on the removal of black pigment in both professional and amateur tattoos with the QSRL. They reported good results, particularly with amateur tattoos but noted several disadvantages, including the need for multiple treatments. They found that amateur tattoos cleared after an average of four to six treatments whereas professional tattoos required one to three additional treatment sessions for complete pigment removal.^{3,4}

In a later study by Taylor et al., 35 amateur and 22 professional blue-black tattoos showed fading or total clearing in 78% of amateur and 23% of professional tattoos. Although these statistics were less than ideal, the authors were optimistic that the QSRL would become the favored treatment for tattoos.⁵

Lowe et al demonstrated that after five treatment sessions, 22 of 28 professional tattoos showed excellent results (>75% improvement).^{6,7} Green pigmented tattoos responded variably but did fade with continued treatment. Kilmer and Anderson reported black and green ink to be the most responsive with other colors requiring significantly more treatments.⁸ They also noted that professional, distally located, recently acquired, or deeply placed tattoos may be more difficult to remove.

Overall, the QSRL was found highly effective for amateur tattoos, moderately effective for black professional tattoos, and less effective for brightly colored professional tattoos.⁹⁻¹¹

Q-switched neodymium:yttrium-aluminum-garnet (QSNd:YAG): The QSNd:YAG laser is a solid-state laser containing a crystal of yttrium-alu-

PRETREATMENT PATIENT CONSULTATION

A physician performing laser tattoo removal should inform the patient of the following before beginning any treatment.

- There is no guarantee for complete removal due to variability in the depth of ink, the density of ink, the composition of the ink, the patient's own immune system, and the chemical makeup of the ink pigment.
- Multiple treatment sessions will be required (usually between five and 15 sessions).
- Laser treatments will be spaced at 6 to 8 week intervals to allow for the skin to heal and for ink elimination.
- Colored tattoos may require more treatments than black ink.
- Older tattoos may respond better than newer tattoos.
- Professional tattoos may require more treatments than amateur tattoos.
- The procedure, although relatively quick, is uncomfortable.
- The amount of ink removed per session varies greatly from patient to patient and even from treatment to treatment in the same patient.
- After tattoo pigment has been removed, the underlying skin may be permanently discolored and have permanent tissue texture changes. ■

minium-garnet (YAG) doped with neodymium (Nd) ions. An Nd:YAG rod is placed within the laser cavity where xenon lamps excite the neodymium ions to provide an emission of 1064 nm with 5ns to 20 ns pulse durations. The longer wavelength of the QSNd:YAG laser allows deeper penetration. In addition, the 1064 nm light interacts less with absorption spectra of melanin thus

decreasing the incidence of hypopigmentation.

A benefit of the YAG laser is that it may be modified with "frequency doubling" or "harmonic generation." The light is passed through a KTP crystal producing green light at a wavelength of 532 nm that achieves good results in the removal of red tattoo pigment, a color that is resistant to treatment with the QSRL.¹²

DeCoste and Anderson showed the QSNd:YAG laser (1064 nm) to be equally as effective as the QSRL in removing black tattoo ink but with less blistering and pain, fewer textural changes, and no hypopigmentation.¹³ Subsequently, Jones et al. and Grevelink et al. demonstrated effective tattoo removal with minimal hypopigmentation or hyperpigmentation.^{14,15} This QSNd:YAG provides a benefit over the QSRL for darker-skinned patients in whom melanin absorption is a concern.

Studies showed that green, yellow, white and red inks were more resistant to QSNd:YAG laser treatment than black ink and cleared less than 25% of the time, even after four treatment sessions. However, the frequency-doubled QSNd:YAG at a wavelength of 532 nm was the treatment of choice for red tattoo pigment, which faded completely in 75% of patients after three treatments.

The Q-switched Nd:YAG laser offers a great advantage for treating tattoos in darker-skinned patients. The 1064 nm wavelength effectively treats black ink and the 532 nm setting treats red, orange and purple ink colors. The primary disadvantage of this laser is the high cost.

Q-switched alexandrite (QSAlex): The QSAlex is a laser containing a chrysoberyl crystal doped with chromium ions. The crystal is placed within the

TATTOO LAW PROJECT IN SWITZERLAND

By 2006, Switzerland will have a federal law regulating the main aspects of tattooing, piercing and permanent makeup practices. The goal of this law is to protect the customers as well as the professionals in these fields.

The first part of the law refers to good practice. According to this law, all professional workers will need to belong to one of the following recognized associations: Swiss Tattooist Association, Swiss Federation of Piercers or the Swiss Professional Association of Beauticians. Workers must be at least 18 years old and have a minimum of 5 years experience. They must follow the post-graduate formation of courses.

Professionals need to be informed of potential risks of transmission of infections such as Hepatitis B and C and HIV,

know how to avoid them as well as what to do if contamination happens. They must not consume drugs or alcohol during work hours or smoke while working.

Concerning hygiene, floors, walls basin and storage must be well organized. Bathrooms must meet hygiene regulations. Workers must have clean hands and nails and instruments must be properly sterilized.

A questionnaire must be presented to all customers to make sure they do not have any contraindications. If any contraindicated conditions, such as heart problems and skin lesions, are noted by the customer, then they must be seen by their physician before receiving treatment. If a customer hides a known condition, he or she could be legally charged.

The toxicology of pigments of tattoo ink will also be regulated under this law. Pigments containing certain aromatic amines or certain dyes will be forbidden because of know toxicity or carcinogenicity. In the future, customers will have access to medical pigments and possibly pigment that is safe for laser removal.

But will this law help protect customers or professionals? There are still questions that remain with this law. Some professional are not well educated and have little respect for the law. It is not clear how the law will be enforced or which federal department will be in charge of enforcing it. ■

— *Maurice Adatto, M.D.*

Dr. Adatto is with the Skinpulse Dermatology Center in Geneva, Switzerland.

COMPARATIVE STUDIES OF Q-SWITCHED LASERS

Multiple comparative studies have been performed assessing the efficacy of Q-switched lasers. Zelickson et al examined the responses of the QSRL, QSNd:YAG, and QSAlex lasers in which 14 commonly used tattoo pigments were injected into guinea pig skin and then treated with each system.²³ This study showed that red brown, dark brown and orange pigments responded best to the QSNd:YAG laser (1064nm). The QSAlex was most effective for removing blue and green pigments. For removing purple and violet pigments, best results were seen using the QSRL. The QSNd:YAG laser (532 nm) removed red pigment the best. Black pigment faded equally with the QSNd:YAG laser and QSAlex.

Levine and Geronemus compared the QSRL to the QSNd:YAG laser by treating half of each of 48 amateur and professional tattoos (39 professional, nine amateur) with each laser.²⁴ The QSRL

proved to be superior in fading black dye in amateur and professional tattoos and removing green pigment. Differences in tattoo removal between the two lasers were not clinically significant in the fading or removal of other colors. Hypopigmentation was found more fre-

Q-SWITCHED LASERS AND THE INK COLOR THEY TREAT BEST

QS Ruby (694 nm)	black/green/blue
QS Alexandrite (755 nm)	black/green/blue
QS Nd:Yag (1064 nm)	blue/black
QS Nd:Yag (532 nm)	red/orange/yellow

quently with the QSRL, especially in darker-skinned patients. The QSNd:YAG laser was superior to the QSRL in the removal of red ink; all tattoos containing red ink were removed completely in one to three treatment sessions.²⁵

Kilmer et al. undertook a prospective,

blinded, controlled study to evaluate the ability of the QSNd:YAG laser to remove 25 professional tattoos and 14 amateur tattoos. Four treatment sessions were performed at 3- to 4-week intervals. More than 75% ink removal was seen in 77% of black tattoos, and greater than 95% ink removal was seen in 28% of tattoos (11 of 39 patients) treated.^{26,27}

McMeekin compared the QSRL to the QSAlex laser in the treatment of 10 black amateur tattoos and found that the QSRL was more effective in clearing tattoos, but hypopigmentation was observed.²⁹ Kaufman et al compared the QSNd:YAG to the QSAlex in the treatment of 50 tattoos and saw better initial as well as long-term results with the QSNd:YAG.^{30,31}

Although all three Q-switched lasers can offer excellent results, the general consensus among dermatologists is that the QSNd:YAG is the current treatment of choice for tattoo removal. ■

laser cavity where flashlamps excite the chromium ions to produce photons with 100 ns pulse durations at a wavelength between the QSRL and the QSNd:YAG lasers of 755 nm. Studies show that the effect of the QSAlex laser is similar to that of the QSRL.¹⁶

Fitzpatrick et al evaluated the ability of the QSAlex laser to remove tattoos in 15 patients with professional tattoos and eight patients with amateur black and blue-black tattoos. Twenty patients (80%) cleared greater than 95% of their ink with an average of 8.9 treatment sessions.^{17,18} Alster reported similar results in amateur and professional tattoos containing black, blue-black and green pigment. The number of treatments required for significant clearing varied from two to 13 with amateur tattoos averaging fewer treatments. Transient hypopigmentation and textural changes occurred in about 50% to 80% and 12% of patients, respectively.^{19,20} In studies on tattoos with multiple colors, Stafford et al reported excellent fading of green, red and purple pigments after QSAlex laser treatment.^{21,22}

MECHANISM OF ACTION

Phagocytosis of pigment by macrophages is the primary method of

elimination however, the precise mechanism of action for removal of tattoo ink treated with Q-switched lasers is not completely known. Some tattoo ink is eliminated as the post-treatment crust is sloughed.

The reason that amateur tattoo ink is eliminated faster than professional ink is most likely due to a less uniform, more shallow distribution in the dermis as well as larger size of the individual ink particles found in amateur tattoos. Because post-laser treated tattoo pigment can be found in regional lymph nodes, it is believed that ink is removed, at least partially, through lymphatic drainage. As a result, tattoos located on distal extremities may require more treatments due to decreased lymphatic drainage while those located centrally may be eliminated quicker.

ANESTHESIA DURING TATTOO REMOVAL

Pain is very personal and while some patients may forgo anesthesia altogether most patients will require some form of local anesthesia. Pre-treatment might include the application of an anesthetic cream under occlusion for 45 to 90 minutes prior to the laser treatment session. If complete anesthesia is desired, it can be administered locally by injections of

1% to 2% lidocaine with epinephrine. Anecdotal reports have noted that patients receiving anesthesia by local injection will require additional treatments as the injection causes mechanical edema, spreading out the tattoo ink, which in turn makes it more difficult for the laser light to act on specific ink particles. It has been reported that infiltration of local anesthesia will add an additional treatment or two.

POST TREATMENT CONSIDERATIONS

Immediately after laser treatment, a slightly elevated, white discoloration with or without the presence of punctuate bleeding is often observed. This white color change is thought to be the result of rapid, heat-formed steam or gas, causing dermal and epidermal vacuolization. Pinpoint bleeding represents vascular injury from photoacoustic waves created by the laser's interaction with tattoo pigment. Minimal edema and erythema of adjacent normal skin usually resolve within 24 hours. Subsequently, a crust appears over the entire tattoo, which sloughs off at approximately 14 days post treatment. As noted above, some tattoo pigment may be found within this crust. Post-operative wound care consists of topically applied antibiotic ointment and

CONTRAINDICATIONS TO LASER TATTOO REMOVAL

Not all patients are ideal candidates for laser tattoo removal. It's important to recognize these relative contraindications and absolute contraindications to laser tattoo removal.

RELATIVE CONTRAINDICATION

- Poorly controlled Diabetes Mellitus
- Thrombocytopenia
- Peripheral Vascular Disease
- Anemia
- Bleeding Disorders
- Rheumatoid Arthritis/
Juvenile Rheumatoid Arthritis
- Subnormal Intelligence or
Psychiatric Disorders
- History of Postinflammatory
Hyperpigmentation
- Chronic Disease
(Crohn's Disease, IBD, etc.)
- Fitzpatrick Skin Type IV or V

ABSOLUTE CONTRAINDICATIONS

- Cellulitis (MRSA)
- Psoriasis
- Lichen Planus
- Lichen Nitidus
- Renal Failure (Acute or Chronic)
- Malignancy
- Multiple Sclerosis
- Vitiligo
- Immunosuppression
- Keloids
- Certain Medications (i.e. Accutane,)
- Collagen Vascular Diseases
- Fitzpatrick Skin Type VI

too colors including flesh tones, light red, white, peach and light brown containing pigments as well as some green and blue tattoo pigments, changed to black when irradiated with Q-switched laser pulses.³⁵ The resulting gray-black color may require more treatments to remove. If tattoo darkening does occur, after 8 weeks the newly darkened tattoo can be treated as if it were black pigment. Darkening of cosmetic ink are shown in the photos on page 75.

Q-switched lasers can rupture blood vessels and aerosolizes tissue requiring a plastic shield or a cone device to protect the laser operator from tissue and blood contact.³⁶ Lastly, protective eye-

a non-occlusive dressing. Fading of the tattoo will be noted over the next 6 to 8 weeks and retreatment energy levels can be tailored depending on the clinical response observed.

SIDE EFFECTS AND COMPLICATIONS

About half of the patients treated with Q-switched lasers for tattoo removal will show some transient changes in the normal skin pigmentation. These changes usually resolve in 6 to 12 months but may be rarely be permanent.

Hyperpigmentation is related to the patient's skin type, with skin types IV, V and VI more prone regardless of the wavelength used. Twice daily treatment with hydroquinones and broad-spectrum sunscreens usually resolves the hyperpigmentation within a few months, although, in some patients, resolution can be prolonged.

Transient textural changes are occasionally noted but often resolve within a few months, however, permanent textural changes and scarring very rarely occur. If a patient is prone to pigmentary or textural changes, longer treatment intervals are recommended. Additionally, if a patient forms a blister or crust post treatment, it is imperative that they do not manipulate this secondary skin change. Early removal of a blister or crust

increases the chances of developing a scar. Additionally, patients with a history of hypertrophic or keloidal scarring need to be warned of their increased risk of scarring.

Local allergic responses to many tattoo pigments have been reported, and allergic reactions to tattoo pigment after Q-switched laser treatment are also possible.³² Rarely, when yellow cadmium sulfide is used to "brighten" the red or yellow portion of a tattoo, a photoallergic reaction may occur.³³ The reaction is also common with red ink, which may contain cinnabar (mercuric sulphide).²⁴ Erythema, pruritus, and even inflamed nodules, verrucous papules, or granulomas may present. The reaction will be confined to the site of the red/yellow ink. Treatment consists of strict sunlight avoidance, sunscreen, interlesional steroid injections, or in some cases, surgical removal. Unlike the destructive modalities described, Q-switched lasers mobilize the ink and may generate a systemic allergic response. Oral antihistamines and anti-inflammatory steroids have been used to treat allergic reactions to tattoo ink.

Studies of various tattoo pigments have shown that a number of pigments (most containing iron oxide or titanium dioxide) change color when irradiated with Q-switched laser energy. Some tat-

wear should be donned at all times during treatment.

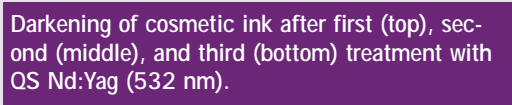
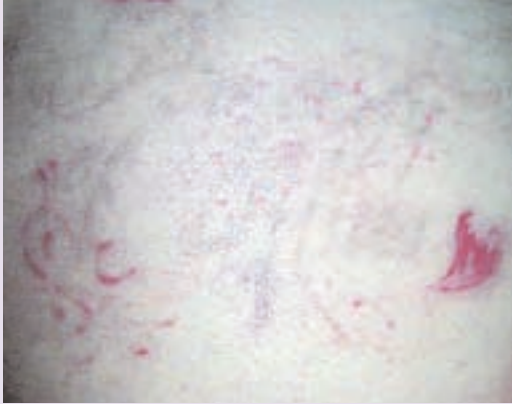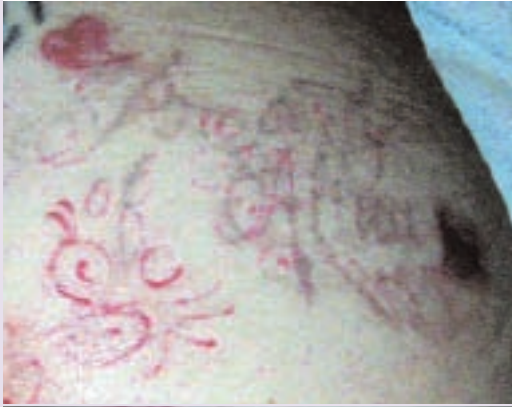FUTURE TRENDS

Beyond the currently available laser treatments, topical treatment modalities for tattoo removal are currently being studied. In 2002, Solis et al performed a study in which imiquimod (Aldara) was evaluated for removal of tattoos in guinea pigs. Imiquimod cream 5% was applied to guinea pigs 6 hours after an application of tattoo ink. Applications were continued every 6 hours for 7 days. At 28 days after the initiation of treatment, the pigment was barely perceptible on microscopy but both inflammation and fibrosis was observed.³⁷ More research is needed to determine whether topical immune response modifiers can effect mature tattoos in humans.

Additionally, in the future it may be possible to define tattoo pigment reflectance characteristics on an individual basis and then choose a wavelength of laser light that will maximize absorption of a particular pigment color theoretically resulting in a faster, more complete laser treatment regime.

BETTER OPTIONS FOR PATIENTS

Methods of tattoo ink removal have been around nearly as long as tattoos



Darkening of cosmetic ink after first (top), second (middle), and third (bottom) treatment with Q-switched Nd:Yag (532 nm).

Q-switched lasers have replaced other methods and are now considered standard treatment for patients seeking tattoo removal. In the coming years, we'll hopefully have even more options available for our patients. ■

Drs. Kirby and Desai are Co-Chief Dermatology Residents at Western University/Pacific Hospital Long Beach Dermatology Program in Torrance, CA. If you would like to contact Dr. Kirby, you may reach him at drwillkirby@yahoo.com.

Francisca Kartono is a Medical Student at Western University of Health Sciences in Pomona, CA.

Disclosure: The authors have no conflict of interest with any subject matter discussed.

References:

1. Goldman L, Blaney DJ, Kindel DJ. Pathology of the effect of the laserbeam on the skin. *Nature*. 1965; 197: 912.
2. Reid, WH, McLeod, PJ, Ritchie, A, Ferguson-Pell, M. Q-switched ruby laser treatment of black tattoos. *Br J Plast Surg*. 1983; 36:455-459.
3. Reid R, Muller S. Tattoo removal by CO laser dermabrasion. *Plast Reconstr Surg* 1980; 65(6): 717-728.
4. Reid WH, Miller ID, Murphy MJ, Paul JP, Evans JH. Q-switched ruby laser treatment of tattoos, a 9-year experience. *Br J Plast Surg* 1990; 43:663-669.
5. Taylor CR, Gange RW, Dover JS, Flotte TJ, Gonzalez E, Michaud N, Anderson RR. Treatment of tattoos by Q-switched ruby laser. A dose-response study. *Arch Dermatol*. 1990; 126(7): 893-899.
6. Lowe NJ. Q-switched ruby treatment of professional tattoos. *Lasers Surg Med Suppl*. 1993; S5: 54.
7. Lowe N, Luftman D, Sawcer D. Q-switched ruby laser: Further observations on treatment of professional tattoos. *J Derm Surg Oncol*. 1994; 20:307-311.
8. Kilmer SL, Anderson RR. Clinical use of the Q-switched ruby and the Q-switched Nd:YAG (1064 nm and 532 nm) lasers for treatment of tattoos. *J Dermatol Surg Oncol*. 1993; 19(4): 330-338.
9. Geronemus RG, Ashinoff R. Use of the Q-switched ruby laser to treat tattoos and benign pigmented lesions of the skin. *Lasers Surg Med Suppl*. 1991; 3: 64.
10. Scheibner A, Kenny G, White W, Wheeland RG. A superior method of tattoo removal using the Q-switched ruby laser. *J Dermatol Surg Oncol*. 1990; 16(12): 1091-1098.
11. Yules, RV, Laub, DR, Honey, R, Vassiliadis, A, Crowley, L. The effect of Q-switched ruby laser radiation on dermal tattoo pigment in man. *Arch Surg* 1967; 95:179-180.
12. Ferguson JE, August PJ. Evaluation of the Nd:YAG laser for treatment of amateur and professional tattoos. *Br J Dermatol*. 1996; 135(4): 586-591.
13. DeCoste SD, Anderson RR. Comparison of Q-switched ruby and Q-switched Nd:YAG laser treatment of tattoos. *Lasers Surg Med Suppl*. 1991; S3: 64.

14. Jones A, Roddey P, Orengo I, Rosen T. The Q-switched Nd:YAG laser effectively treats tattoos in darkly pigmented skin. *Dermatol Surg* 1996; 22(12): 999-1001.
15. Grevelink JM, Duke D, van Leeuwen RL, Gonzalez E, DeCoste SD, Anderson RR. Laser treatment of tattoos in darkly pigmented patients: efficacy and side effects. *J Am Acad Dermatol*. 1996; 34(4): 653-656.
16. Garcia C, Clark RE. Tattoo removal using the Alexandrite laser. *N C Med J*. 1995; 56(7): 336-338.
17. Fitzpatrick RE, Goldman MP, Ruiz-Esparza J. Use of the alexandrite laser (755 nm, 100 nsec) for tattoo pigment removal in an animal model. *J Am Acad Dermatol*. 1993; 28(5 Pt 1): 745-750.
18. Fitzpatrick RE, Goldman MP. Tattoo removal using the alexandrite laser. *Arch Dermatol*. 1994; 130(12): 1508-1514.
19. Alster TS. Successful elimination of traumatic tattoos by the Q-switched alexandrite (755-nm) laser. *Ann Plast Surg* 1995; 34(5): 542-545.
20. Alster TS. Q-switched alexandrite laser treatment (755 nm) of professional and amateur tattoos. *J Am Acad Dermatol*. 1995; 33(1): 69-73.
21. Stafford TJ, Lizek R, Tan OT. Role of the Alexandrite laser for removal of tattoos. *Lasers Surg Med*. 1995; 17(1): 32-38.
22. Stafford, TJ, Lizek, R, Tan, OT. Removal of colored tattoos with the Q-switched alexandrite laser. *Plast Reconstr Surg*. 1995; 94:313-320.
23. Zelickson BD, Mehregan D, Zarrin AA, Coles C, Hartwig P, Olson S, Leaf-Davis J. Clinical, histologic, and ultrastructural evaluation of tattoos treated with three laser systems. *Lasers Surg Med*. 1994; 15:364-372.
24. Levine VI, Geronemus RG. Tattoo removal with the Q-switched ruby laser and the Q-switched Nd:YAG laser: a comparative study. *Cutis* 1995; 55(5):291-296.
25. Kilmer SL, Lee MS, Anderson RR. Treatment of multi-colored tattoos with the Q-switched Nd:YAG laser (532 nm): a dose response study with comparison to the Q-switched ruby laser. *Lasers Surg Med Suppl*. 1993; 5: 54.
26. Kilmer SL, Lee M, Farinelli W, Grevelink JM. Q-switched Nd:YAG laser (1064 nm) effectively treats Q-switched ruby laser resistant tattoos. *Lasers Surg Med Suppl*. 1992; 4: 72.
27. Kilmer SL, Lee MS, Grevelink JM, Flotte TJ, Anderson RR. The Q-switched Nd:YAG laser effectively treats tattoos. A controlled, dose-response study. *Arch Dermatol*. 1993; 129(8): 971-978.
28. McMeekin TO, Goodwin DP. A comparison of the alexandrite laser (755 nm) with the Q-switched ruby laser (694 nm) in the treatment of tattoos. *Lasers Surg Med Suppl*. 1993; S5: 43.
29. Kaufman R, Boehncke WH, Konig K, Hibst R. Comparative study of Q-switched Nd:YAG and alexandrite laser treatment of tattoos. *Lasers Surg Med*. 1993; S5: 54.
30. Kaufmann R, Hibst R. Pulsed Erbium:YAG laser ablation in cutaneous surgery. *Lasers Surg Med*. 1996; 19(3): 324-330.
31. Ashinoff R, Levine VI, Soter NA. Allergic reactions to tattoo pigment after laser treatment. *Dermatol Surg* 1995; 21(4): 291-294.
32. Sowden JM, Byrne JP, Smith AG, Hiley C, Suarez V, Wagner B, Slater DN. Red tattoo reactions: X-ray microanalysis and patch-test studies. *Br J Dermatol*. 1991; 124(6): 576-580.
33. Antony FC, Harland CC. Red ink tattoo reactions: successful treatment with the Q-switched 532nm Nd:Yag laser. *Br J Dermatol*. 2003; 149:94-98.
34. Anderson RR, Geronemus R, Kilmer SL, Farinelli W, Fitzpatrick RE. Cosmetic tattoo ink darkening. A complication of Q-switched and pulsed-laser treatment. *Arch Dermatol*. 1993; 129(8): 1010-1014.
35. Kilmer SL, Casparian JM, Wimberly JM, Anderson RR. Hazards of Q-switched lasers. *Lasers Surg Med Suppl*. 1993; 5: 56.
36. Solis RR, Diven DG, Colome-Grimmer MI, Snyder N 4th, Wagner RF Jr. Experimental nonsurgical tattoo removal in a guinea pig model with topical iniquimod and tretinoin. *Dermatol Surg*. 2002; 28:83-87.

themselves. Previous removal modalities left patients with pain, discoloration, tissue texture changes, and residual pigment. Our ability to remove tattoos, however, has advanced greatly in the last decade and previous modalities for tattoo removal have been replaced by highly selective laser techniques. The use of Q-switched lasers has been able to help the vast majority of patients seeking tattoo removal by offering a low risk, highly effective therapy with minimal side effects. Because they offer bloodless, low risk, effective treatment,