


TATTOO REMOVAL TECHNIQUES





PART ONE OF OUR TWO-PART SERIES FOCUSES ON THE HISTORY OF TATTOOS AND THE EARLY OPTIONS FOR REMOVAL.

BY WILLIAM KIRBY, D.O., TEJAS DESAI, D.O., AND FRANCISCA KARTONO, B.S.

Tattoos are not new — they've been around since ancient times. In 1991, at the border of Austria and Italy in the Alp Mountains, the body of a man was found. Subsequent carbon dating showed that this well-preserved frozen human had died approximately 5,300 years earlier.¹ Of note was the fact that he had 59 purposely placed skin markings, making this discovery one the best-documented cases of tattoo placement in ancient man.

The word “tattoo” is derived from the Tahitian word “tattau” and the Polynesian (Marquesan) word “tatu”, which mean “to mark”, and were first mentioned in 1769 by explorer James Cook's after his expedition to the South Pacific. The practice of permanently decorating the human body, however, has been in existence for thousands of years with origins tracing back to the Stone Age (12,000 BC).²

Today it is estimated that there are more than 4,000 tattoo parlors in the United States and more than 5% of the adult population has a tattoo for either decorative or cosmetic purposes.

EARLY TATTOO METHODS

There is a wide variety of means by which tattoo ink can be injected into the skin. Simple skin pricking with solid needles coated in ink, scratching or abrading the skin and then applying ink to the excoriations through mechanical rubbing, or even drawing threads coated with pigmented ashes through the skin are some of the many early methods. However, the one thing all tattoo techniques have in common is the depth of pigment placement; for the ink to become permanent it must be placed in the dermis.

MODERN TATTOOING

In 1876, Thomas Edison patented a tattooing device called the autographic printer, which he intended to be used as an engraving device for hard surfaces. In 1891, Samuel O'Reilly modified Edison's machine by changing the tube system and incorporating a rotary-driven electromagnetic oscillating unit, which enabled the machine to drive the needle.

The modern tattoo machine is a steel instrument fitted with needles that puncture the skin at the rate of 50 to 3,000 times a minute. Powered by a foot switch, the tattoo machine uses an up-and-down motion to puncture the epidermis and drive ink particles between 0.6 mm and 2.2 mm into the dermis.

TATTOO INK, COLOR AND PARTICLE SIZE

Tattoo artists use exogenous pigments of unknown purity and identity. In both professional and amateur tattoos, the location of the ink pigment varies greatly as does the size and shape of the ink particles themselves. Amateur tattoo inks consist of simple, carbon particles originating from burnt wood, cotton, plastic or paper, or from a variety of inks, including India ink, pen ink and vegetable matter. Professional artists have access to more than 100 different colors. Black ink is the most common color seen in professional tattoos, followed by red, blue, green, yellow and orange. More recent tattoos have a greater range of colors, including shades of pink, brown, purple and even fluorescent colors. Some tattoo inks are actually a mixture of colors with a wide range of shades and are thus difficult to classify as a single pigment.

The FDA currently lists tattoo inks as “color additives” for use on the skin. Truth be told, because ink manufacturers are not required to list the composition of their products, in the vast majority of cases, neither tattoo artists nor patients have any idea of the exact make-up of the tattoo ink.

Regardless of the composition of the tattoo pigment, the microscopic appearances of all pigments are similar; Taylor et al. found black pigment granules in tattoos to vary in diameter from 0.5 μm to 4.0 μm .³ Colored ink granules were noted to be larger than black ink granules. Additionally, there is variability in regard to the size of the pigment clusters formed when pigment granules aggregate. For the most part, professional tattoos have smaller clusters that are approximately 145 μm while amateur tattoo have clusters of approximately 180 μm .^{4,5}

HISTOLOGY

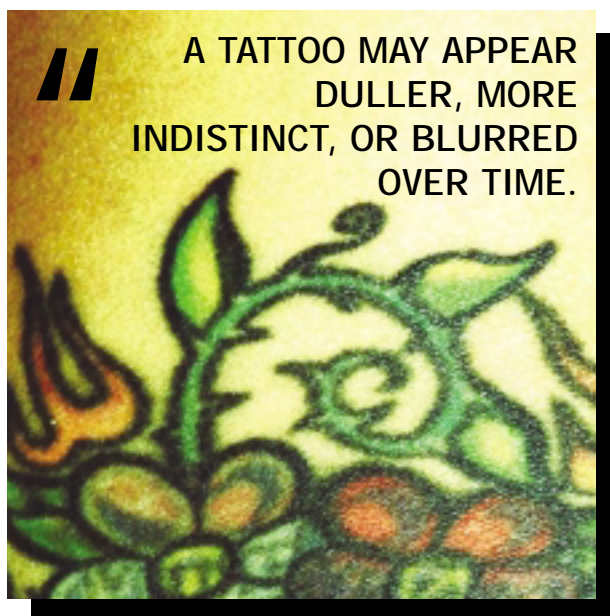
Immediately following tattoo injection, ink particles are found within large phagosomes in the cytoplasm of both keratinocytes and phagocytic cells, including fibroblasts, macrophages and mast cells.⁶ Additionally, the epidermis, epidermal-dermal junction, and papillary dermis appeared homogenized.^{6,7}

At 1 month, biopsies show that the basement membrane begins to reform, and aggregates of ink particles are noted within basal cells. In the dermis, ink-containing phagocytic cells are concentrated along the epidermal-dermal border below a layer of granulation tissue that is closely surrounded by collagen.⁶⁻⁸ Again, ink particles are present in keratinocytes, macrophages, and fibroblasts. Additionally, transepidermal elimination of ink particles outward through the epidermis is still in progress 1 month following ink injection. Pigment is not seen within mast cells, endothelial cells, pericytes, Schwann cells, in the lumina of blood and lymphatic vessels, or extracellularly.⁷⁻⁹

In biopsy specimens obtained at 3 months and at 40 years, a prominent

network of connective tissue is found to surround each fibroblast that contains ink particles, effectively entrapping and immobilizing the cell. This presence of ink particles only in dermal fibroblasts supports the theory that fibroblasts are responsible for the stable intradermal life span of the tattoo. The life span of these fibroblasts is unknown and may persist throughout the individual's life.^{7,10}

Clinically, a tattoo may appear duller, more indistinct, or blurred over time. Kilmer noted that although biopsies provide considerable detail regarding the dermatopathology of tattoo pigment, they do not fully explain dermal tattoo ink changes. One proposed theory is that



during sun exposure, some Langerhan cells will undergo apoptosis while others migrate into the dermis and a minor inflammatory reaction occurs. The inflammatory reaction occurs in the epidermis but it also involves the dermis. Such a reaction causes the recruitment of more phagocytic immune cells to the area, and it has been suggested that a tattoo may change clinically through the action of these phagocytic cells.¹¹ Biopsies of older tattoos demonstrate pigment in the deep dermis and eventually ink may appear in the regional lymph nodes.

TATTOO REMOVAL TECHNIQUES

In many cases, patients with tattoos regret their decision to decorate their

skin. The presence of a tattoo may put a strain on interpersonal relationships and can sometimes serve as an obstacle to meaningful employment. While most people keep tattoo(s) for life, it has been estimated that 50% of individuals with tattoos regret the decision to decorate their skin.

Through the years, various methods of tattoo removal have been attempted.

Dermabrasion was once the primary method of tattoo removal; it removed tattoos by sloughing off layers of skin until reaching the ink. For centuries individuals have used this method simply using any sharp object. In the 1950s and 1960s, a rapidly spinning wheel or a wire brush abraded skin frozen with a refrigerant to produce a hard surface. The procedure tended to be rather traumatic and the biological particulates that were aerosolized could carry infectious agents. Hypertrophic scarring occurred frequently, post-operative pain was significant, and most patients reported a result more unsightly than the original tattoo.¹²⁻¹⁴

Salabrasion was first described in 543 AD by Aetius, a Greek physician to the Byzantine court in his 16-volume medical text *Medicæ Artis Principes*. Salabrasion involves abrading the superficial dermis with coarse granules of common table salt and a moist abra-

sive pad. Salt is then reapplied to the wound surface and left under occlusion for 24 to 36 hours.^{15,16} Commonly, residual tattoo pigment remains and textural changes are noted after the wound heals.¹⁷

Liquid nitrogen is commonly used to destroy superficial cutaneous lesions. However, its role in tattoo removal is limited because the destruction leads to unpredictable results including hypopigmentation, scarring and prolonged healing time.¹⁸

In 1888, Variot G. Nouveau traumatized the skin surface with punctures and incisions and then applied **tannic acid and silver nitrate** in an attempt to remove tattoo ink.¹⁹ This technique resulted in a less significant scar than that

LASER PRINCIPLES”

The term “laser” is an acronym for light amplification by the stimulated emission of radiation. The therapeutic action of laser energy is based on complex interactions between laser light and biological tissues.

The process begins when an energy source stimulates the lasing medium causing an atom to move from a resting state to an excited state. When the atom returns to its resting state, a photon of light energy is released. The released photon collides with atoms still in an excited state, leading to light amplification.

The emitted laser light is monochromatic, meaning it is of a single wavelength (measured in nanometers) that is determined by the specific medium through which the light was passed: crystal, liquid dye, or gas.

While ordinary light travels in all directions at once, laser light is collimated and coherent — it has parallel (non-divergent) beams, which gives the laser the ability to maintain the same spot size regardless of the distance traveled.

When laser light strikes the skin, the light may be absorbed, reflected, transmitted or scattered. The Grotthus-Draper law, the first law of photobiology, states that light must be absorbed by tissue for a clinical action to take place.

Absorption determines the depth of penetration of laser energy. In general, as the wavelength increases, so does the depth of penetration. Lasers using longer wavelengths of light can penetrate deeper. The energy absorbed is known as fluence.

The amount of absorption is determined by the wavelength and the chromophore

present. The common cutaneous chromophores include water, hemoglobin, melanin and, for purposes of this article, tattoo ink. When tattoo ink absorbs a specific wavelength of light, a photothermal reaction occurs leading to target destruction from the conversion of absorbed energy into heat. (See figure 1 below for the absorption spectra.)

Pulse width, or pulse duration (measured in nanoseconds or milliseconds) is the length of time that laser light is in contact with the skin, and the thermal relaxation time is defined as the time required for the temperature generated by the absorbed energy within the target chromophore to cool to one-half its original value immediately after irradiation.

In the 1980s, Anderson and Parrish’s principal of selective photothermolysis revolutionized the laser treatment of tattoos.²⁹⁻³¹ They proposed that if a wavelength was well absorbed by the target chromophore and the pulse width was equal to or shorter than the target’s thermal relaxation time, the heat generated would be confined to the target. Selective photothermolysis is laser light-mediated damage to very specific chromophores of the skin. The application of this theory allows for highly selective destruction of a target in the skin, like a tattoo, with minimal unwanted injury to the surrounding area containing other chromophores like melanin and hemoglobin.

Laser parameters including wavelength, pulse duration and fluence can be tailored to maximize tattoo ink destruction and minimize thermal damage to surrounding tissue.

from the application of more caustic chemicals but was noted to leave residual tattoo pigment.²⁰

Phenol solution and trichloroacetic acid have been used to treat tattoo ink, but they, too, leave hypopigmented scars.^{21,22} Repeat application is hazardous and may result in a full-thickness burn that requires skin grafting.

Thermal injury via fire, hot coals, and cigarettes has been used for centuries to try to remove unwanted tattoos, usually with significant scarring. Thermal cautery, electrocautery, and infrared coagulation are equally unpredictable.^{21,23}

Surgical excision of skin containing tattoo pigment is still common but may result in scarring because of limitations in wound closure. However, tattoos located in areas of adequate skin laxity may be removed with simple excision with the added benefit of a single, relatively inexpensive treatment.^{24,25}

All of the aforementioned treatments offer unpredictable results and may result in scarring, hypopigmentation, pain and incomplete resolution of the tattoo ink.

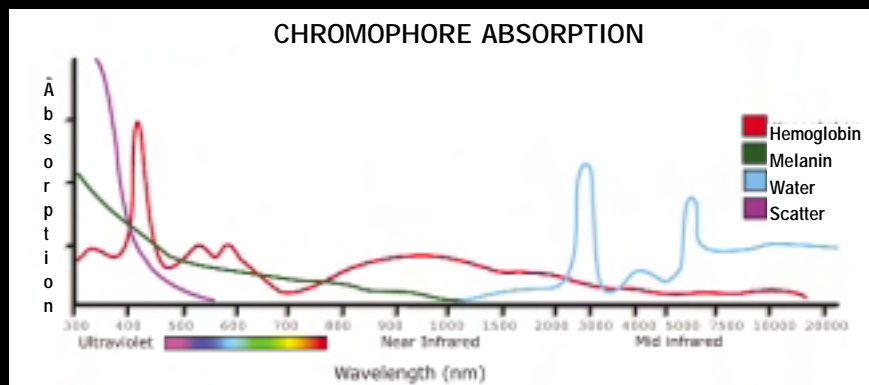
LASER HISTORY

Albert Einstein first introduced the concept of stimulated light emission in 1917. Although modern lasers are based on his theory, it took many years before a functioning laser was available. In 1959, advancements in technology allowed Maiman to develop a laser using a ruby crystal to produce red light, and in 1963, Goldman used ruby laser treatment for a variety of cutaneous applications.²⁶ Goldman’s initial report of successful tattoo removal using ruby and Nd:YAG lasers appeared in 1967.^{27,28} In the 1970s most cutaneous research focused on argon and carbon dioxide laser use. The ability to remove a tattoo with a laser with minimal side effects was enhanced greatly when, in the early 1980s, Anderson and Parrish developed pulsed lasers and the theory of selective photothermolysis.²⁹⁻³¹

EARLY LASER USE IN TATTOO REMOVAL

The Argon Laser. In 1979 an argon laser was used for tattoo removal in 28 patients. Hypertrophic scarring occurred in 21% of these patients and half of the patients had residual tattoo

Figure 1. Laser absorption spectra of cutaneous chromophores.³²



pigment while complete removal of tattoo pigment was noted in 8 patients (29%) with acceptable cosmetic results.³³ In a subsequent study, 20 of 60 patients experienced complete removal of tattoo pigment without scarring, with amateur tattoos responding slightly better than professional tattoos. Unfortunately, hypertrophic scarring occurred in 35% of the patients, and residual tattoo pigment remained in 67%.³⁴

The argon laser offers selective absorption of energy from its 488 nm and 514 nm wavelengths by tattoo pigment. Its usefulness, however, is limited by melanin and hemoglobin absorption, resulting in unwanted damage to tissue surrounding the tattoo pigment. Thus, even though the authors demonstrated selective absorption of laser energy by tattoo pigment, they also noted extensive diffusion of heat from all absorbing chromophores resulting in non-selective destruction.³⁵

The carbon dioxide laser (CO₂). The carbon dioxide laser emits a continuous beam at 10,600 nm, a wavelength completely absorbed by water, and reports of successful tattoo removal with the carbon dioxide laser first appeared in 1978.³⁶ The original objective of carbon dioxide treatment was to vaporize tissue and remove all tattoo pigment in one treatment session. Attempts to confine the depth of tissue vaporization to the precise level of tattoo pigment resulted in a wound of variable depth because tattoo ink is deposited at different depths even within the same tattoo.³⁷ Histologic evaluation of the wounds revealed loss of dermis and subcutaneous tissue up to a depth of 5 mm.³⁸ Because of a prolonged healing time and scarring, most physicians decided against complete pigment removal in one session with the CO₂ laser. They instead treated patients more conservatively, relying on macrophage engulfment and transepidermal removal of tattoo pigment during the healing phase. Residual pigment was retreated after healing was complete.

With the carbon dioxide laser, layers of skin are removed to expose the pigment, and the wound is allowed to heal by re-epithelialization from adjacent skin. Dermal tissue is reconstituted by fibrosis and scar tissue. Although excellent results

can be obtained, because there is no color selective light absorption, nonspecific thermal damage to adjacent dermal structures occurs and, therefore, virtually all patients have some form of secondary scar formation making both the argon laser and the carbon dioxide laser less than ideal treatment modalities.³⁹⁻⁴²

BETTER TREATMENT OPTIONS

Over time, better laser removal options have been discovered. Next month, we'll look at current treatment modalities with the Q-switched lasers and also discuss some possible tattoo removal techniques for the future.

Drs. Kirby and Desai are Co-Chief Dermatology Residents at Western University/Pacific Hospital Long Beach Dermatology Program in Torrance, CA.

Francisca Kartono is a Medical Student at Western University of Health Sciences in Pomona, CA.

References:

- Hambly WD. *The History of Tattooing and Its Significance*. Gale Research Co; 1974.
- Goldstein N, Sewell M III. Tattoos in different cultures. *J Dermatol Surg Oncol*. 1979; 5(11): 857-856.
- Taylor CR, Anderson RR, Gange RW, Michaud NA, Flotte TJ. Light and electron microscopic analysis of tattoos treated by Q-switched ruby laser. *J Invest Dermatol*. 1991; 97(1): 131-136.
- Christensen HE, Schmidt H. The ultrastructure of tattoo marks. *Acta Pathol Microbiol Scand [A]*. 1972; 80(4): 573-576.
- Silberberg I, Leider M. Studies of a red tattoo: Appearances in electron microscope, and analysis by chemical means, laser microprobe and selected-area diffraction of tattooed material. *Arch Dermatol*. 1970; 101(3): 299-304.
- Kilmer SL, Anderson RR. Clinical use of the Q-switched ruby and the Q-switched Nd:YAG (1064 nm and 532 nm) lasers for treatment of tattoos. *J Dermatol Surg Oncol*. 1993; 19(4): 330-338.
- Lea PJ, Pawlowski A. Human tattoo: Electron microscopic assessment of epidermis, epidermal-dermal junction, and dermis. *Int J Dermatol*. 1987; 26(7): 453-458.
- Goldstein AP VII. Histologic reactions in tattoos. *J Dermatol Surg Oncol*. 1979; 5(11): 896-900.
- Laub DR, Yules RB, Arras M, Murray DE, Crowley L, Chase RA. Preliminary histopathological observation of Q-switched ruby laser radiation on dermal tattoo pigment in man. *J Surg Res*. 1968; 8(5): 220-224.
- Mann R, Klingmuller G. Electron-microscopic investigation of tattoos in rabbit skin. *Arch Dermatol Res*. 1981; 271(4): 367-372.
- Dover JS, Margolis RJ, Polla LL, Watanabe S, Hruza GJ, Parrish JA, Anderson RR. Pigmented guinea pig skin irradiated with Q-switched ruby laser pulses. Morphologic and histologic findings. *Arch Dermatol*. 1989; 125(1): 43-49.
- Boo-Chai K. The decorative tattoo-its removal by dermabrasion. *Plast Reconstr Surg*. 1963; 32: 559.
- Ceille RI. Curettage after dermabrasion-techniques of removal of tattoos. *J Dermatol Surg Oncol*. 1979; 5: 905.

- Clabaugh WA. Tattoo removal by superficial dermabrasion. Five-year experience. *Plast Reconstr Surg*. 1975; 55(4): 401-405.
- Crittenden FM. Salabrasion-removal of tattoos by superficial abrasion with table salt. *Cutis*. 1971; 7: 295.
- Koerber WA Jr, Price NM. Salabrasion of tattoos. A correlation of the clinical and histological results. *Arch Dermatol*. 1978; 114(6): 884-888.
- Colver GB, Dawber RP. Tattoo removal using a liquid nitrogen cryospray. *Clin Exp Dermatol*. 1984; 9(4): 364-366.
- Colver GB, Dawber RP. The removal of digital tattoos. *Int J Dermatol*. 1985; 24(9): 567-568.
- Van der Velden EM, Van der Walle HB, Groote AD. Tattoo Removal: Tannic Acid Method of Variot. *Int J Dermatol*. 1993; 32(5): 376-380.
- Fogh H, Wulf HC, Poulsen T, Larsen P. Tattoo removal by overtattooing with tannic acid. *J Dermatol Surg Oncol*. 1989; 15(10): 1089-1090.
- Colver GB, Cherry GW, Dawber RP. Tattoo removal using infra-red coagulation. *Br J Dermatol*. 1985; 112(4): 481-485.
- Piggot TA, Norris RW. The treatment of tattoos with trichloroacetic acid: experience with 670 patients. *Br J Plast Surg*. 1988; 41(2): 112-117.
- Scutt RW. The chemical removal of tattoos. *Br J Plast Surg*. 1972; 25(2): 189-194.
- Bunke HJ, Conway H. Surgery of decorative and traumatic tattoos. *Plast Reconstr Surg*. 1957; 20: 67.
- Wheeler ES, Miller TA. Tattoo removal by split thickness tangential excision. *West J Med*. 1976; 124(4): 272-275.
- Goldman L, Wilson RG, Hornby P. Radiation from a Q-switched ruby laser. *J Invest Dermatol*. 1965; 44: 69.
- Goldman L, Rockwell RJ, Meyer R, Otten R, Wilson RG, Kitzmiller, KW. Laser treatment of tattoos: a preliminary survey of three years clinical experience. *JAMA*. 1967; 201:841-844.
- Goldman L, Rockwell RJ, Meyer R. Laser treatment of tattoos. *JAMA*. 1967; 201: 163.
- Anderson, RR, Parrish, JA. The optics of human skin. *J Invest Dermatol*. 1981; 77:13-19.
- Anderson, RR, Parrish, JA. Optical properties of skin. In: Regan, JD, Parrish, JA, eds. *The Science of Photomedicine*. New York, NY: Plenum Press; 1982: 147-194.
- Anderson RR, Parrish JA. Selective photothermolysis: precise microsurgery by selective absorption of pulsed radiation. *Science*. 1983; 220(4596): 524-527.
- Herd RM, Dover JS, Arndt KA. Basic laser principles. *Dermatol Clin*. 1997; 15(3):355-372.
- Apfelberg DB, Maser MR, Lash H. Argon laser treatment of decorative tattoos. *Br J Plast Surg*. 1979; 32(2): 141-144.
- Apfelberg DB, Laub DR, Maser MR, Lash H. Pathophysiology and treatment of decorative tattoos with reference to argon laser treatment. *Clin Plast Surg*. 1980; 7(3): 369-377.
- Diette KM, Bronstein BR, Parrish JA. Histologic comparison of argon and tunable dye lasers in the treatment of tattoos. *J Invest Dermatol*. 1985; 85(4): 368- 373.
- McBurney EI. Carbon dioxide laser treatment of dermatologic lesions. *South Med J*. 1978; 71(7): 795-797.
- Reid R, Muller S. Tattoo removal with laser. *Med J Aust*. 1978; 1(7): 389.
- Beacon JP, Ellis H. Surgical removal of tattoos by carbon dioxide laser. *J R Soc Med*. 1980; 73(4): 298-299.
- Apfelberg DB, Maser MR, Lash H, et al. Comparison of argon and carbon dioxide laser treatment of decorative tattoos: a preliminary report. *Ann Plast Surg*. 1985; 14(1): 6-15.
- Bailin PL, Ratz JL, Levine HL. Removal of tattoos by CO₂ laser. *J Dermatol Surg Oncol*. 1980; 6(12): 997-1001.
- Levins PC, Grevelink JM, Anderson RR. Q-switched ruby laser treatment of tattoos. *Lasers Surg Med Suppl*. 1991; 3: 63.
- Brady SC, Blokmanis A, Jewett L. Tattoo removal with the carbon dioxide laser. *Ann Plast Surg*. 1979; 2(6): 482-490.